
Retained IOL fragment and corneal decompensation after pseudophakic IOL exchange

Richard S. Hoffman, MD, I. Howard Fine, MD, Mark Packer, MD

A 72-year-old man had exchange of a foldable silicone multifocal intraocular lens (IOL) by transection, removal, and monofocal IOL replacement. One month after the exchange, irreversible corneal edema developed and penetrating keratoplasty was performed. At the time of the corneal transplant, a small silicone fragment was discovered in and removed from the anterior chamber. Histologic evaluation of the patient's cornea demonstrated an absence of corneal endothelium, suggesting the fragment was the etiology of the corneal decompensation.

J Cataract Refract Surg 2004; 30:1362–1365 © 2004 ASCRS and ESCRS

Despite continuing improvements in intraocular lens (IOL) power calculations and designs, occasional postoperative refractive surprises and subjective visual complaints necessitate IOL removal and exchange. Foldable IOLs have advantages for insertion and exchange; both can be accomplished through a 3.0 mm incision, allowing a reduction in surgically induced astigmatism. Methods for removing a foldable IOL through a small incision include transecting it with a cutting instrument or refolding the IOL in the anterior chamber and removing it intact with the folding instrument.^{1–3}

Pseudophakic IOL exchange can cause corneal edema as a result of intraoperative corneal endothelial trauma. We present a case of corneal decompensation resulting from an occult retained intraocular foreign body after pseudophakic IOL exchange. Intraoperative and postoperative recommendations for avoiding this complication are discussed.

Case Report

A 72-year-old white man presented initially with a complaint of reading difficulty. The best spectacle-corrected visual acuity (BSCVA) was 20/30⁻² in the right eye and 20/50⁻² in the left eye. The patient had 2+ nuclear sclerotic cataract in both eyes in addition to a mild epiretinal membrane in the right eye and mild amblyopia in the left eye. Small-incision cataract surgery was performed with implantation of bilateral Array[®] multifocal IOLs (AMO).

The patient was ultimately dissatisfied with the quality of his vision. One year after cataract surgery, the BSCVA was 20/40 in the right eye and 20/50 in the left eye. The patient returned to the surgeon and requested that the IOLs be exchanged for monofocal ones. Before undergoing the initial cataract surgery and the lens exchange corneal endothelial cell counts were measured at 2200 cells/mm² and 1890 cells/mm² in both eyes, respectively. An IOL exchange was performed in the right eye using the Mackool Foldable Lens Removal System (Impex, Inc.). The surgeon described the procedure as atraumatic but stated that several passes of the Mackool scissors were required to transect the IOL.

One week after the IOL exchange, glare had disappeared in the right eye and the uncorrected visual acuity (UCVA) was 20/40. The eye was quiet, and the patient was pleased with the eradication of photic phenomena. However, 1 month after the IOL exchange, the patient presented to the operating surgeon with complaints of pain and blurred vision in the right eye. The eye had diffuse corneal edema and mild to moderate cellular reaction in the anterior chamber. The surgeon prescribed topical steroids, hyperosmotics, and atropine for pain. One month later, the eye was quiet but the corneal stromal edema persisted; the UCVA could be improved to

Accepted for publication September 3, 2003.

From a private practice, Eugene, Oregon, USA.

Presented in part at the ASCRS Symposium on Cataract, IOL and Refractive Surgery, San Francisco, California, USA, April 2003.

None of the authors has a financial or proprietary interest in any material or method mentioned.

Reprint requests to Richard S. Hoffman, 1550 Oak Street, Suite 5, Eugene, Oregon 97401, USA. E-mail: rshoffman@finemd.com.




Figure 1. (Hoffman) Endothelial cell counts after pseudophakic IOL exchange. *Left:* Counts in the right eye were unattainable despite attempts to measure the superior corneal endothelium. *Right:* The cell count in the left eye was 2445 cells/mm² centrally.

only 20/100 in the right eye. The patient was referred for a corneal consultation.

Three months after the IOL exchange, the patient's eye remained quiet but there was no improvement in corneal edema despite aggressive treatment with topical prednisolone acetate 1% every hour and sodium chloride 5% (Muro 128®) every 2 hours. A corneal endothelial cell count was unattainable in the right eye and normal at 2400 cells/mm² in the left eye (Figure 1).

Penetrating keratoplasty (PKP) was eventually performed in the right eye for visual rehabilitation. No intraocular foreign body was seen after the cornea was removed. However, after the graft was sutured into place and the residual ophthalmic viscosurgical device (OVD) was irrigated out of the anterior chamber with balanced salt solution (BSS®), a small, clear foreign body was seen behind the donor graft. The foreign body was removed from the anterior chamber; it appeared to be a small sliver of the silicone IOL removed by the original surgeon (Figure 2). Histologic evaluation of the patient's cornea revealed a complete absence of endothelial cells (Figure 3).

The patient had an uneventful postoperative course. Nine months after corneal transplantation, the graft was clear and all but 2 interrupted 10-0 nylon sutures had been removed (Figure 4), yielding a visual acuity of 20/40 with a correction of +0.50 +1.50 × 60.

Discussion

The causes of pseudophakic bullous keratopathy are numerous. It can develop secondary to preexisting endothelial disease or from multiple intraoperative factors in-

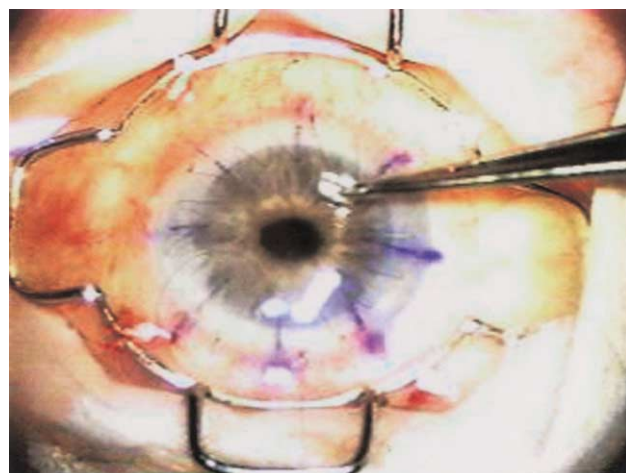


Figure 2. (Hoffman) A small silicone IOL fragment immediately after removal from the anterior chamber.

cluding IOL to corneal touch, ultrasound damage, drug toxicity, excessive instrumentation, and Descemet's membrane detachment. Postoperative causes include vitreous touch, IOL to endothelial touch, flattening of the anterior chamber, peripheral anterior synechias, pseudophacodonesis, and inflammation.⁴

With the conversion from large-incision extracapsular cataract extraction to phacoemulsification, retained crystalline lens fragments within the anterior chamber have become an additional cause of corneal decompensation.⁵⁻⁷ These fragments result in corneal edema through a presumed mechanism of repeated cor-

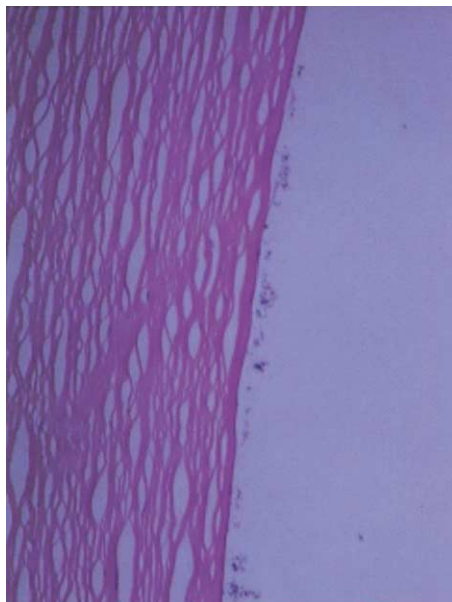


Figure 3. (Hoffman) Magnification of the patient's posterior corneal surface, demonstrating absence of corneal endothelium. (Basophilic material along Descemet's membrane is a fixative artifact.)

neal endothelial trauma and cell loss. Remaining endothelial cells will spread over bare Descemet's membrane and eventually succumb to fragment trauma until the density of remaining cells falls below the threshold needed to maintain cornea clarity.

Pseudophakic fragments in the anterior chamber as an etiology for corneal edema is rare. A literature review revealed only 2 reports of corneal decompensation associated with pseudophakic IOL fragments. One report involved a broken haptic from an anterior cham-

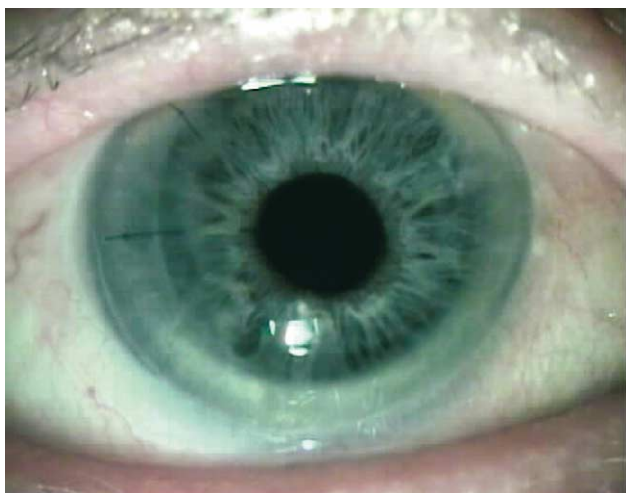

Figure 4. (Hoffman) Nine months after PKP with 2 remaining interrupted sutures.

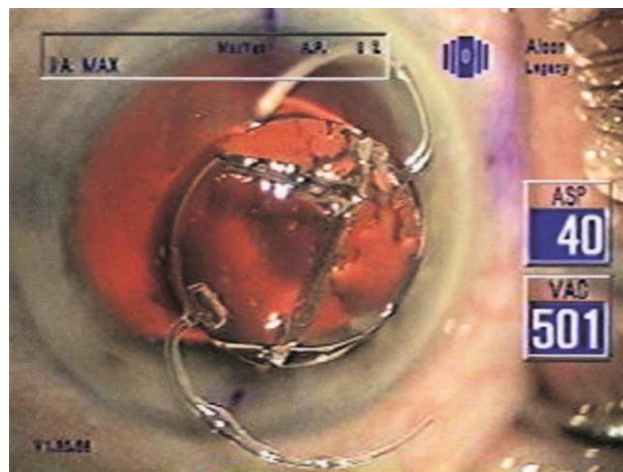


Figure 5. (Hoffman) The Pharmacia Z9000 IOL was transected with a wire-snare after a crack was observed in the optic immediately after cartridge insertion. The IOL was reassembled on the ocular surface, demonstrating complete extraction. Three rather than 2 pieces were created secondary to transection through the cartridge-induced crack.

ber IOL⁸ and the other, a fractured haptic from a single-piece poly(methyl methacrylate) posterior chamber IOL.⁹

The growing use of foldable IOLs¹⁰ may present a new entity of corneal edema secondary to these IOLs' unique properties. When foldable IOLs have to be removed or exchanged because of insertion damage, decentration, unwanted photic phenomena, or refractive error,¹¹ IOL transection with a wire-snare or scissors enables extraction through small incisions. This removal technique also facilitates the creation of small IOL fragments or slivers, especially when multiple passes of the cutting instrument are necessary to complete IOL transection.

In our patient, it is unlikely that corneal decompensation resulted from endothelial cell damage at the time of IOL exchange, since the immediate postoperative visual acuity was good and there was no evidence of significant corneal edema for at least 1 week after the exchange. Although the anterior chamber inflammation may have contributed to corneal edema, the mild to moderate iritis would not be consistent with a complete absence of corneal endothelium, as demonstrated in the histologic specimen.¹² Additionally, edema secondary to acute iritis should have resolved once the inflammation was eliminated. The more obvious etiology for the corneal decompensation was the occult IOL fragment repeatedly traumatizing the corneal endothelium and

creating continual cell loss similar to that which occurs with retained nuclear material in the anterior chamber.

There are simple intraoperative and postoperative techniques to prevent the development of irreversible corneal edema resulting from retained IOL fragments. Regardless of the instrument used to transect an IOL for extraction, small fragments can be created. By removing each piece of the transected IOL and reassembling them externally on the corneal surface like jigsaw-puzzle pieces, the surgeon can demonstrate that the entire IOL has been removed (Figure 5). Discontinuities in the externalized IOL would indicate a possible retained fragment. Additionally, after the new IOL is inserted and the OVD removed, irrigation of the anterior chamber angle with balanced salt solution will assist in dislodging occult fragments that may have been created and not recognized.

After a pseudophakic IOL exchange, if the cornea is initially clear but later decompensates, a foreign body should be suspected and gonioscopy performed. Corneal edema in most instances will be more prominent inferiorly, since the effects of gravity tend to position the IOL fragment in the inferior angle, initially compromising the inferior corneal endothelium.¹³ If the retained fragment can be identified and removed early postoperatively, before profound cell loss develops, the corneal edema should improve and PKP may be avoided.

References

1. Koch H-R. Lens bisector for silicone intraocular lens removal. *J Cataract Refract Surg* 1996; 22:1379–1380
2. Koo EY, Lindsey PS, Soukiasian SH. Bisecting a foldable acrylic intraocular lens for explantation. *J Cataract Refract Surg* 1996; 22:1381–1382
3. Neuhann TH. Intraocular folding of an acrylic lens for explantation through a small incision cataract wound. *J Cataract Refract Surg* 1996; 22:1383–1386
4. Sugar A. Surgical trauma: pseudophakic and aphakic corneal edema. In: Krachmer JH, Mannis MJ, Holland EJ, eds, *Cornea*. St Louis, MO, Mosby, 1997; 1423–1435
5. Gedde SJ, Karp CL, Budenz DL. Retained nuclear fragment in the anterior segment. *Arch Ophthalmol* 1998; 116:1532–1533
6. Bohigian GM, Wexler SA. Complications of retained nuclear fragments in the anterior chamber after phacoemulsification with posterior chamber lens implant. *Am J Ophthalmol* 1997; 123:546–547
7. Braude LS, Schroeder RP. Retained nuclear fragment 1 year after uncomplicated phacoemulsification cataract extraction with posterior chamber intraocular lens implant [letter]. *Arch Ophthalmol* 1999; 117:847–848
8. Maguen E, Nesburn AB, Jackman N, Macy JL. Broken semiflexible intraocular lens implant. *Am J Ophthalmol* 1985; 99:170–172
9. Eleftheriadis H, Sahu DN, Willekens B, et al. Corneal decompensation and graft failure secondary to a broken posterior chamber poly(methyl methacrylate) intraocular lens haptic. *J Cataract Refract Surg* 2001; 27:2047–2050
10. Leaming DV. Practice styles and preferences of ASCRS members—2001 survey. *J Cataract Refract Surg* 2002; 28:1681–1688
11. Mamalis N. Complications of foldable intraocular lenses requiring explantation or secondary intervention—2001 survey update. *J Cataract Refract Surg* 2002; 28:2193–2201
12. Setälä K. Corneal endothelial cell density in iridocyclitis. *Acta Ophthalmol* 1979; 57:277–286
13. Laibson PR. Inferior bullous keratopathy and unsuspected anterior chamber foreign body. *Arch Ophthalmol* 1965; 74:191–197